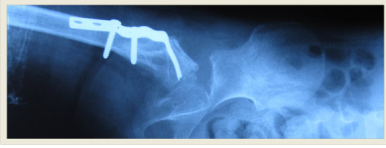

Destruction of both hip joints / Pictures

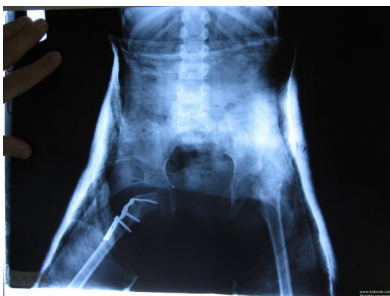Saturday, 04 September 2010 18:36 - Last Updated Friday, 27 May 2011 08:25



4 yr old boy with past history of bilateral hip septic arthritis, presented with waddling gait 6 months after treatment.

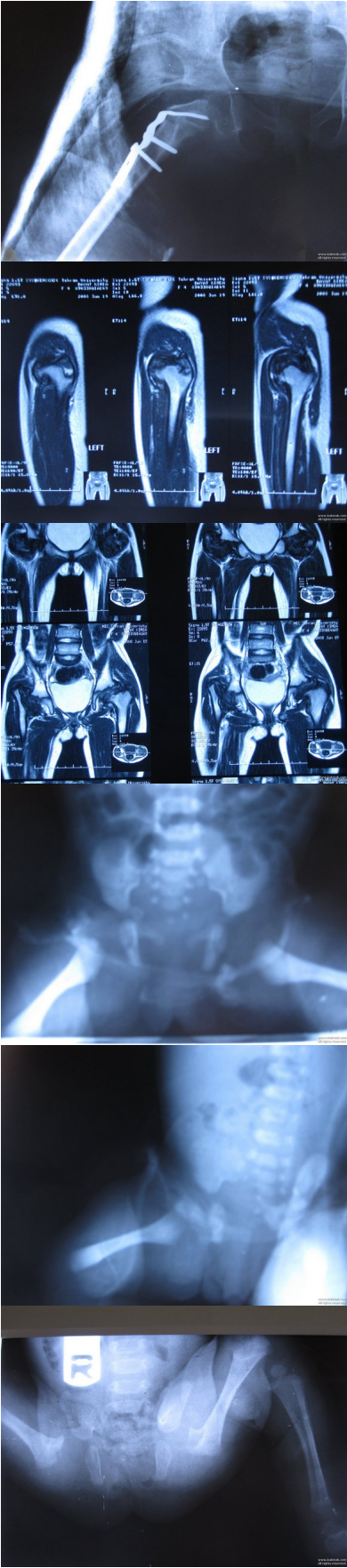
Pelvic x-rays and MRI showed marked destruction of both hip joints.

Patient underwent osteotomy for right hip and another surgery for left hip was planned after recovery.



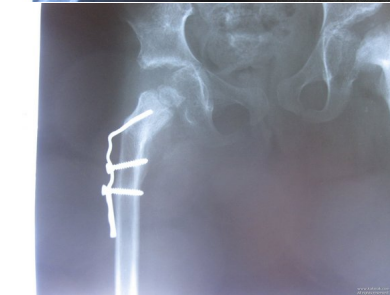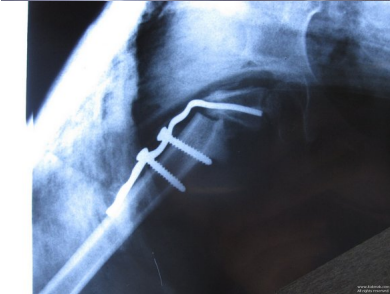
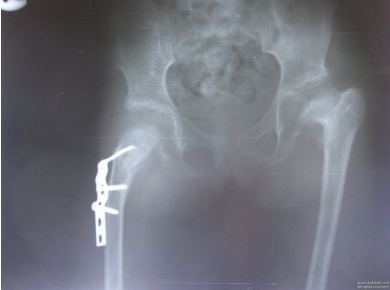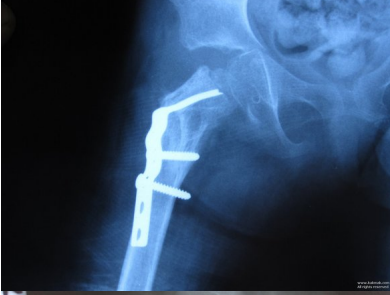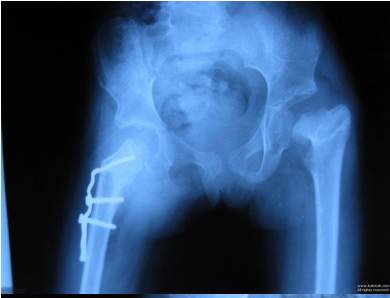
Destruction of both hip joints / Pictures

Saturday, 04 September 2010 18:36 - Last Updated Friday, 27 May 2011 08:25



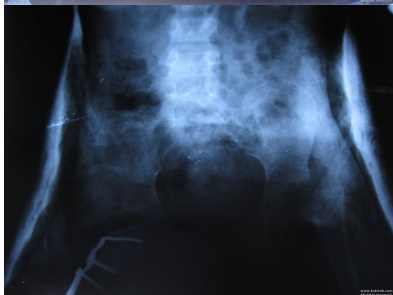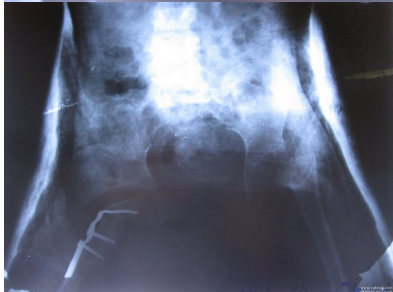
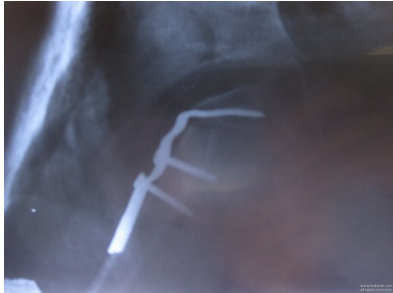
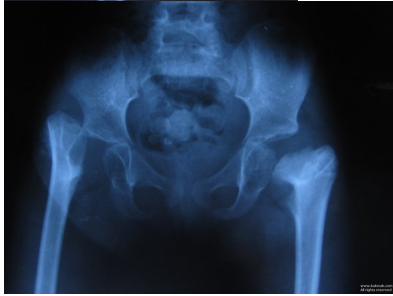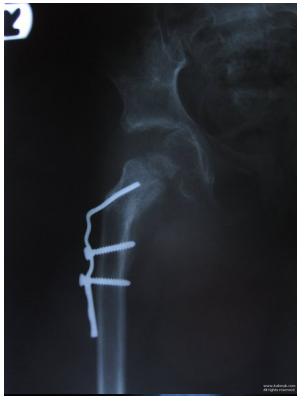Destruction of both hip joints / Pictures

Saturday, 04 September 2010 18:36 - Last Updated Friday, 27 May 2011 08:25



Destruction of both hip joints / Pictures

Saturday, 04 September 2010 18:36 - Last Updated Friday, 27 May 2011 08:25



Destruction of both hip joints / Pictures

Saturday, 04 September 2010 18:36 - Last Updated Friday, 27 May 2011 08:25

